

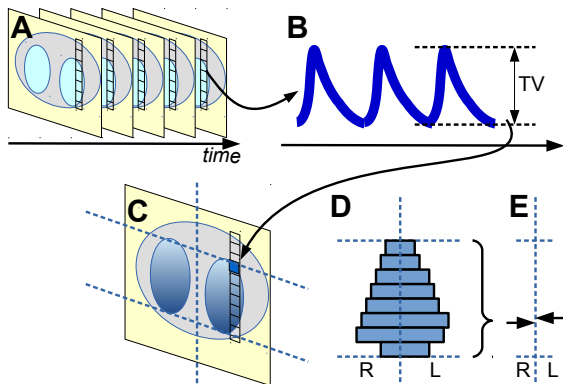
Phase-contrast functional EIT images

EIT 2018, Edinburgh, UK
12 June 2018

Andy Adler¹, Martijn Miedema² David Tingay³

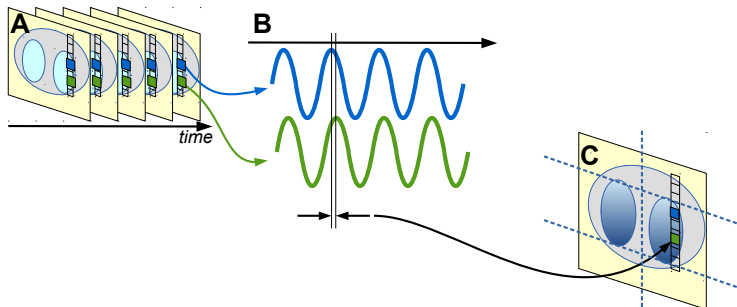
¹Carleton University, Ottawa, ²Academic Medical Center, Amsterdam,
Netherlands, ³University of Melbourne, Australia

functional EIT \Rightarrow fEIT



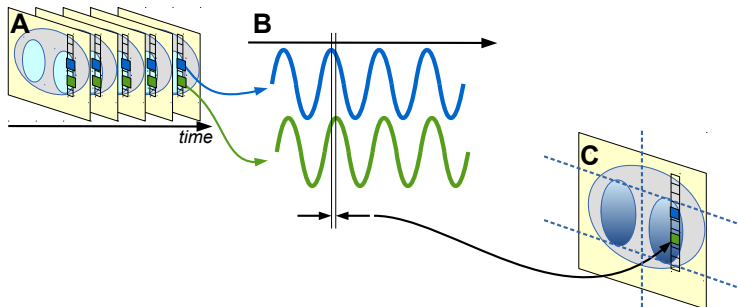
(A) EIT image sequence. (B) analysis of waveforms to calculate a TV, and generation of which fEIT images (C). (D) horizontal histogram of breathing in L/R slices. (E) L/R centre of gravity

phase-delay fEIT



(A) EIT image sequence. (B) waveforms at two pixels with a phase difference, which is represented as the (C) phase-delay fEIT image

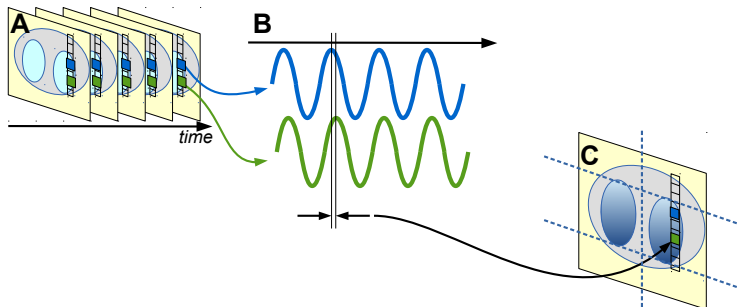
phase-delay fEIT



(A) EIT image sequence. (B) waveforms at two pixels with a phase difference, which is represented as the (C) phase-delay fEIT image

Challenges

phase-delay fEIT

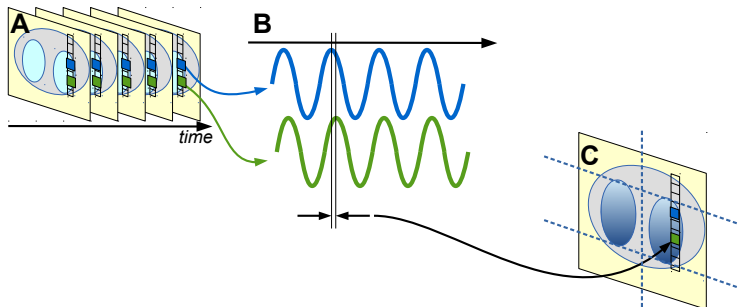


(A) EIT image sequence. (B) waveforms at two pixels with a phase difference, which is represented as the (C) phase-delay fEIT image

Challenges

- Reference phase

phase-delay fEIT

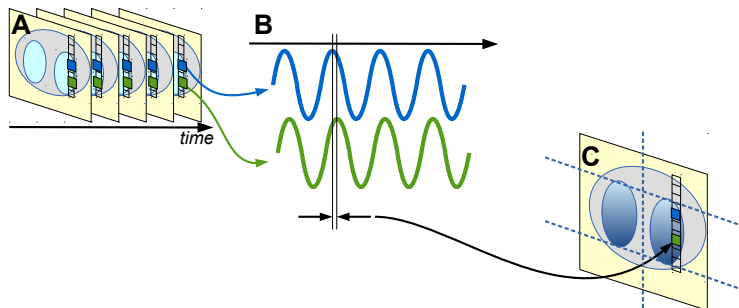


(A) EIT image sequence. (B) waveforms at two pixels with a phase difference, which is represented as the (C) phase-delay fEIT image

Challenges

- Reference phase \rightarrow Average signal

phase-delay fEIT



(A) EIT image sequence. (B) waveforms at two pixels with a phase difference, which is represented as the (C) phase-delay fEIT image

Challenges

- Reference phase \rightarrow Average signal
- 360° phase changes

phase-delay fEIT: calculation

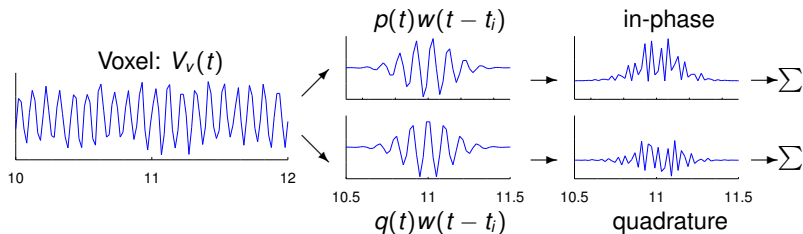
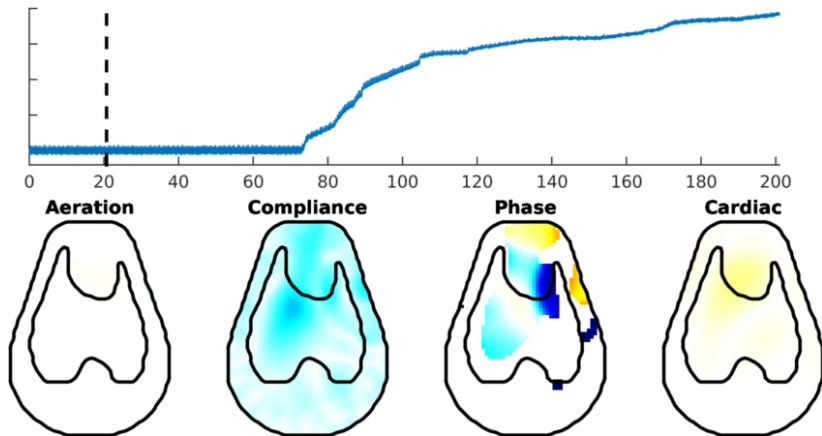


Figure: Phase detection: voxel waveform (*left*) multiplied by windowed p , q (*centre*) to produce (*right*) which are summed.

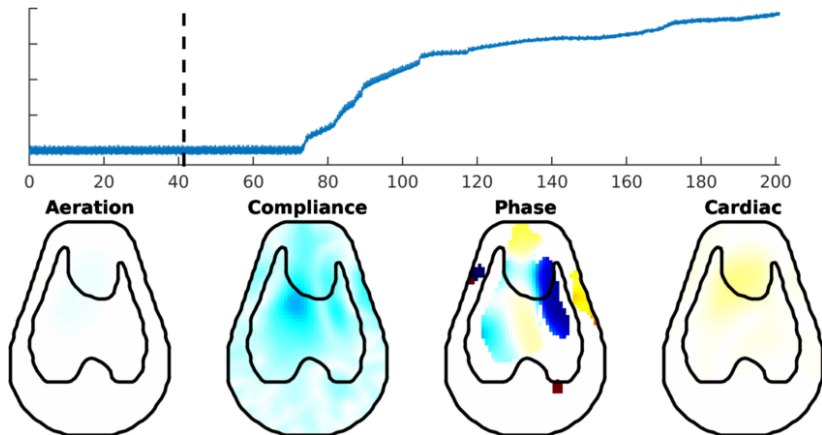
Experimental Methods

- Extremely premature neonatal lambs
- Instrumented pre-birth
- Swisstom pioneer set: 32 electrodes, lamb belt, GREIT
- EIT placed immediately after birth but before first breath
- High frequency oscillatory ventilation (10 Hz)
- Various care parameters tested
- Spontaneous pneumothorax is fairly common

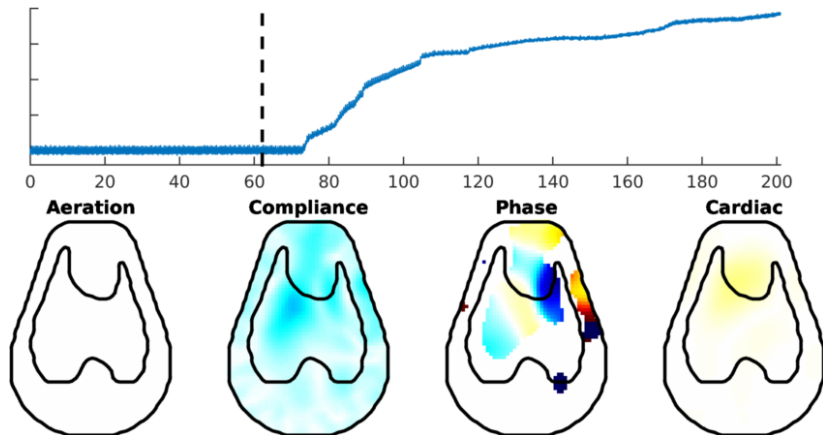
phase-delay fEIT of Pneumothorax



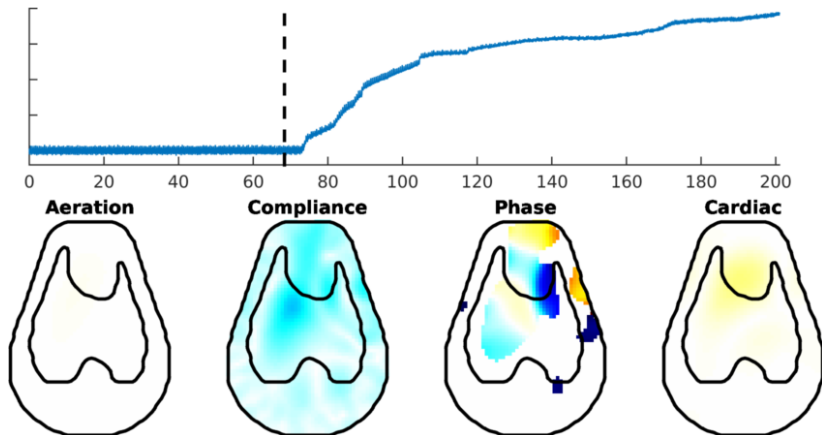
phase-delay fEIT of Pneumothorax



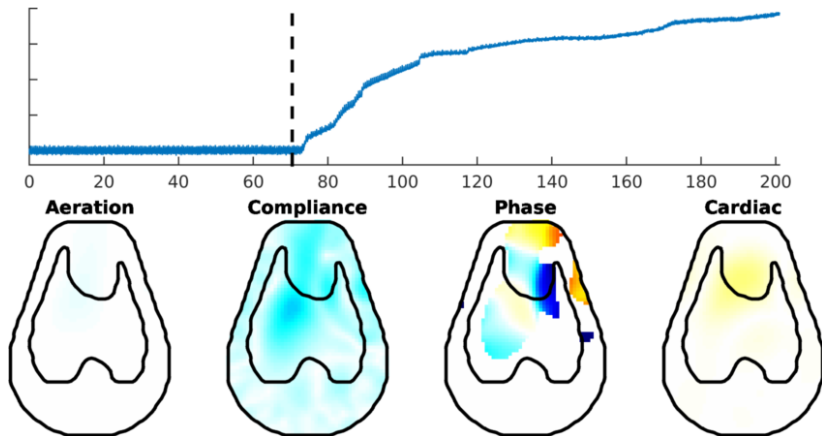
phase-delay fEIT of Pneumothorax



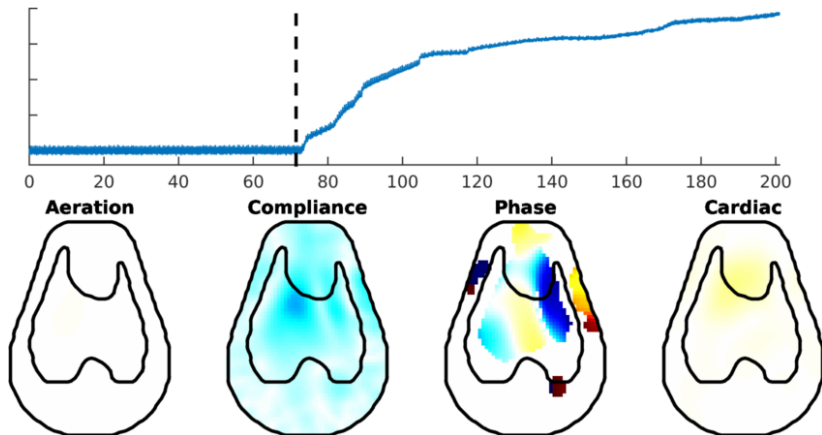
phase-delay fEIT of Pneumothorax



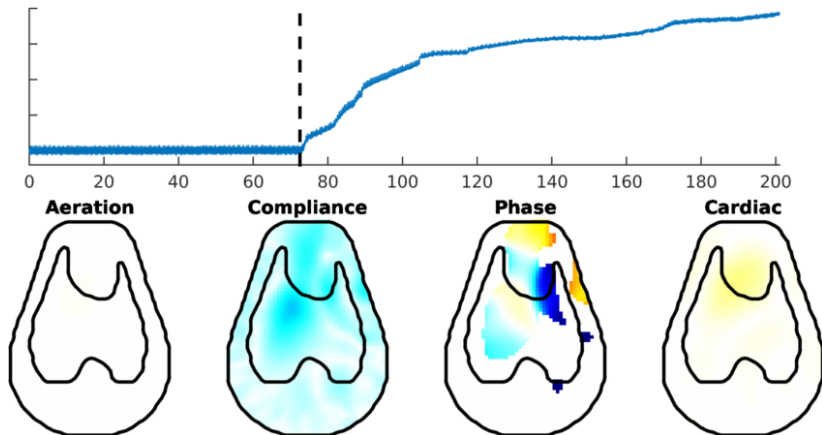
phase-delay fEIT of Pneumothorax



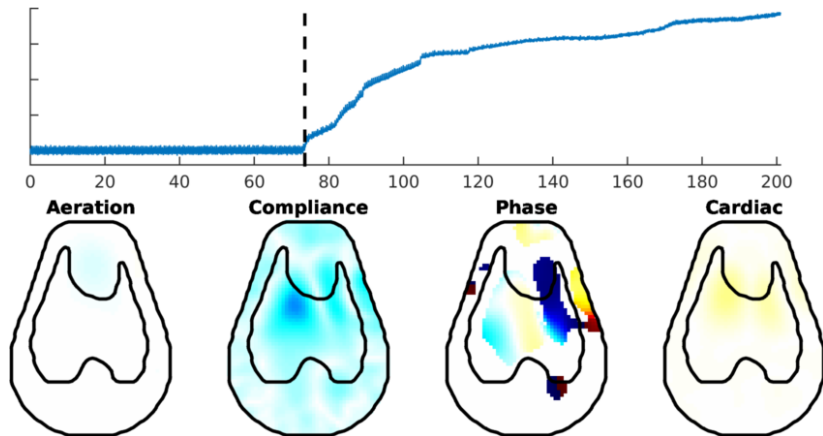
phase-delay fEIT of Pneumothorax



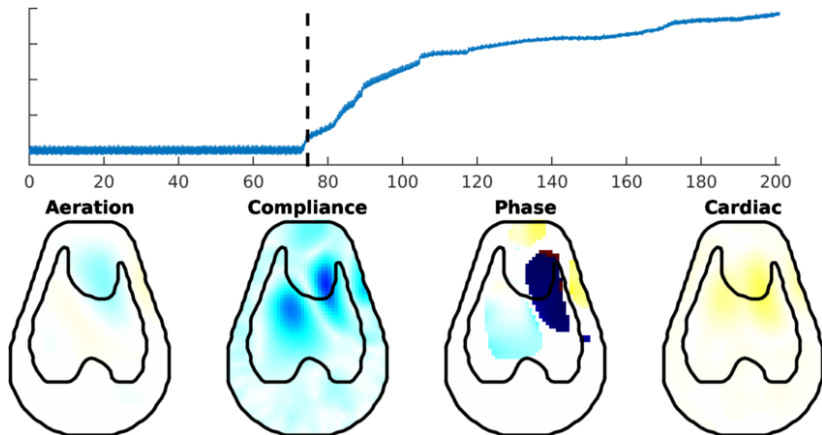
phase-delay fEIT of Pneumothorax



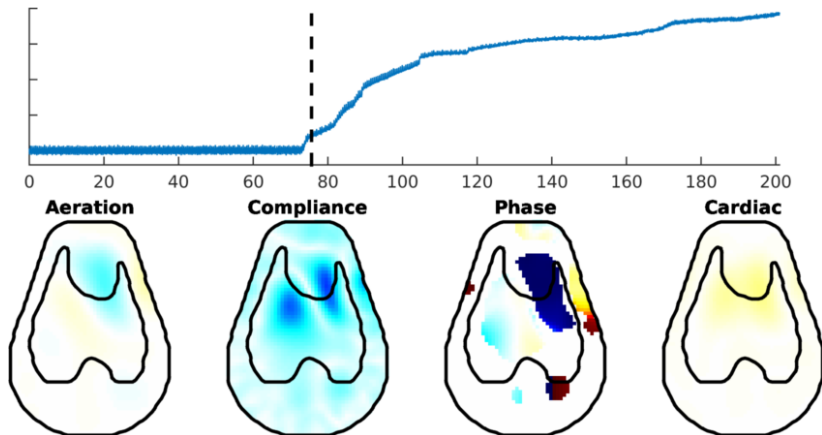
phase-delay fEIT of Pneumothorax



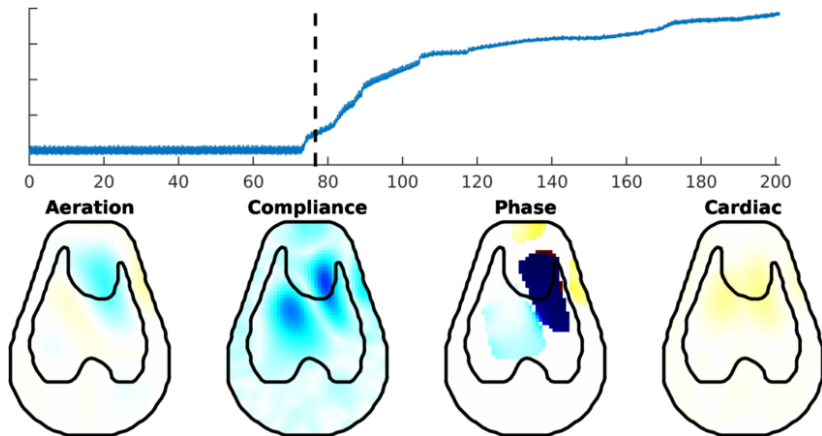
phase-delay fEIT of Pneumothorax



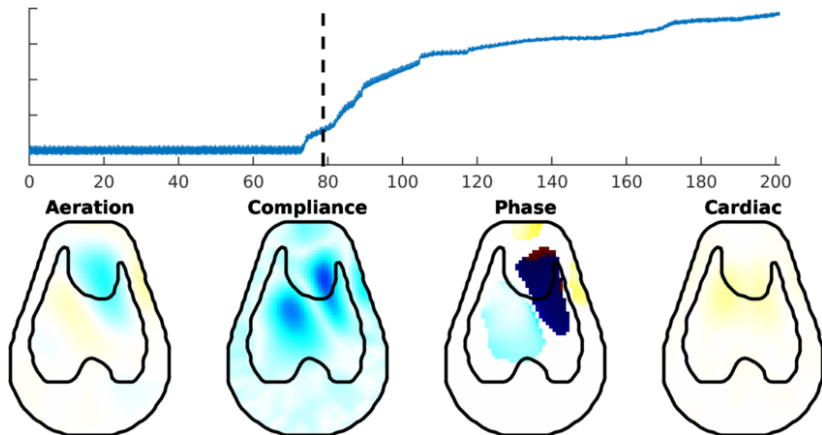
phase-delay fEIT of Pneumothorax



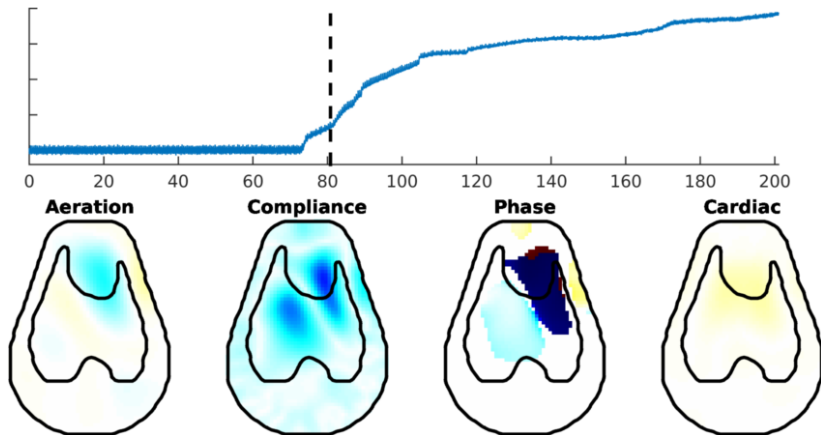
phase-delay fEIT of Pneumothorax



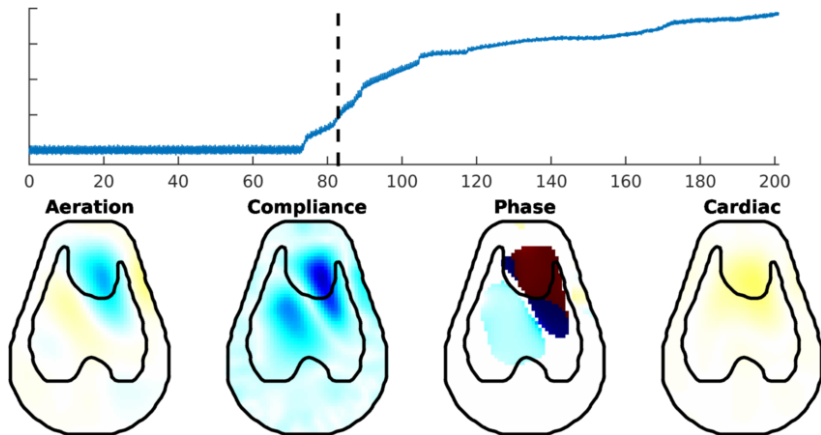
phase-delay fEIT of Pneumothorax



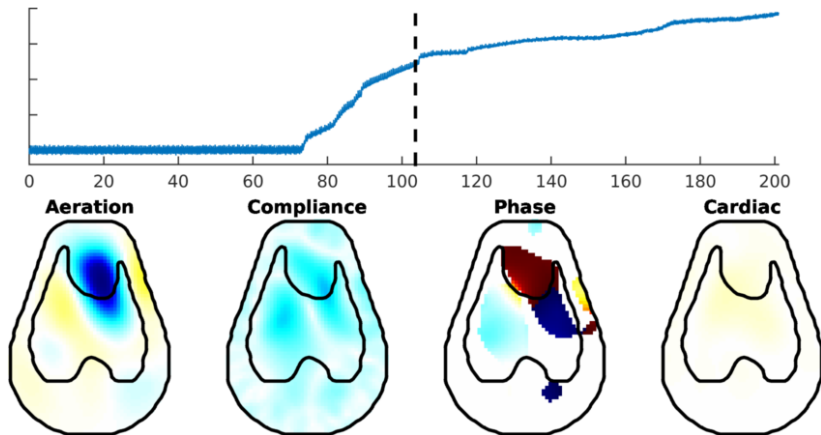
phase-delay fEIT of Pneumothorax



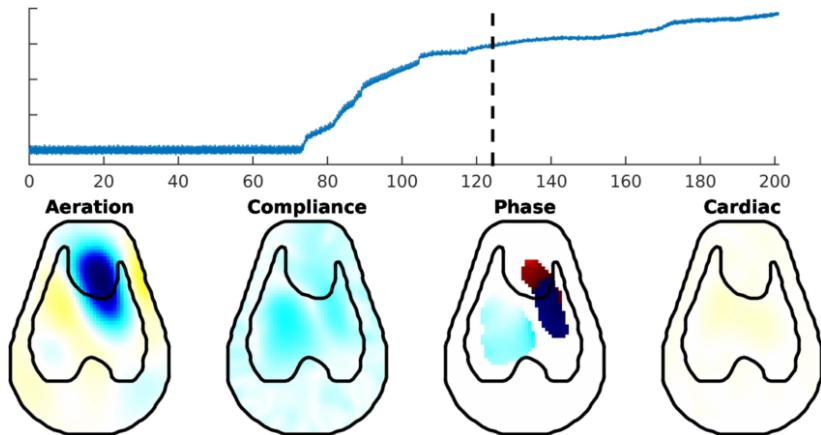
phase-delay fEIT of Pneumothorax



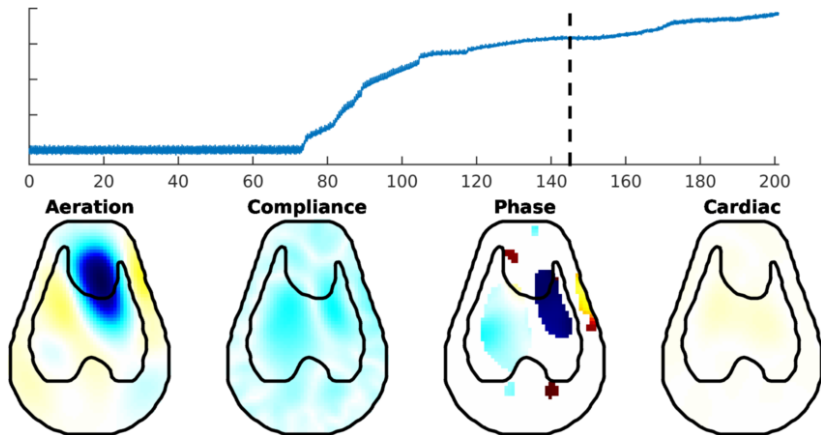
phase-delay fEIT of Pneumothorax



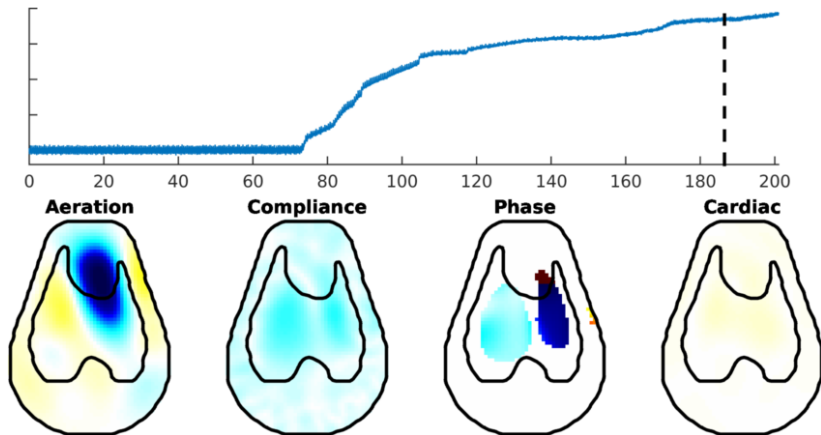
phase-delay fEIT of Pneumothorax



phase-delay fEIT of Pneumothorax



phase-delay fEIT of Pneumothorax



Phase-contrast functional EIT images

EIT 2018, Edinburgh, UK
12 June 2018

Andy Adler¹, Martijn Miedema² David Tingay³

¹Carleton University, Ottawa, ²Academic Medical Center, Amsterdam,
Netherlands, ³University of Melbourne, Australia