

# *EIT monitoring of the liquid-ventilated lung*

Andy Adler<sup>1</sup>, Étienne Fortin-Pellerin<sup>2</sup>, Mathieu Nadeau<sup>2</sup>,  
Jonathan Vandamme<sup>2</sup>, Julien Mousseau<sup>2</sup>, Philippe  
Micheau<sup>2</sup>, Michaël Sage<sup>2</sup>, & Jean-Paul Praud<sup>2</sup>.

<sup>1</sup>Carleton University, Ottawa, Ontario, Canada

<sup>2</sup>Université de Sherbrooke, Québec, Canada

ICEBI & EIT 2016  
Stockholm, Sweden  
21 June 2016

# Liquid ventilation

- Perflubron (high solubility for  $O_2$ ,  $CO_2$ ) instead of air for respiratory gas exchange.
- Density ( $\rho \approx 2$ ) helps it keep open dependent lung regions, which can collapse (atelectasis) or undergo cyclical opening.
- Proposed Application #1: Protective ventilation strategy
  - extremely premature neonates
  - ARDS patients
- Proposed Application #2:
  - ultrafast cooling following cardiac arrest

# Liquid Assisted Ventilation (1989–2000)

**TABLE 2—Reports of Clinical Trials of Humans Treated With LAV**

Year	Reference #	Populations	N	Diagnosis
1989–94	4, 158, 159	Preterm neonates	6	Respiratory failure
1996	61	Preterm neonates	13	Severe RDS
1996	62, 160	Term neonates	4	CDH on ECLS
1996	164	8 weeks–5.5 years	6	Respiratory failure–ECLS
1996	165	1–17 years	10	ARDS
1996	54–56, 166, 167	19–55 years	10	ARDS on ECLS
1997	52, 59, 161	Term neonates	6	ARDS/CDH
1997	168	Adults	65	Respiratory failure

(Wolfson et al, Pediatric Pulmonology, 1998)

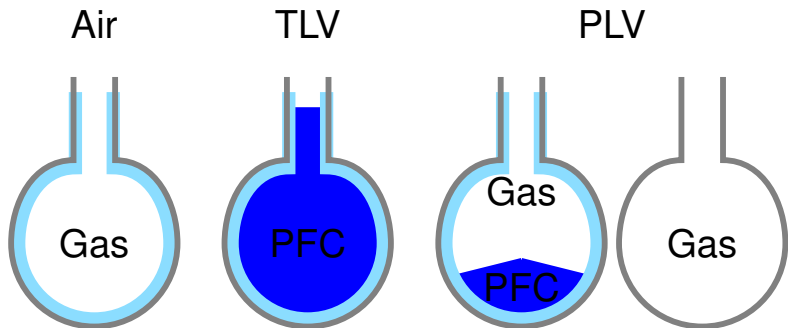
Partial Liquid Ventilation 13 newborns. (Leach et al, N Engl J Med, 1998)

*Partial liquid ventilation leads to clinical improvement and survival in some infants with severe respiratory distress syndrome who are not predicted to survive.*

## Liquid Assisted Ventilation (2000–)

- 2000 Clinical Research phases II and III, 56 centres / 311 patients “PLV ... does not improve outcome compared with CMV.” (Kacmarek et al, Resp. Crit. Care, 2005)
- 2009 “Only full lung liquid ventilation with a dedicated liquid ventilator is the most logical approach to apply LAV efficiently and reliably in humans” (Costantino, Micheau et al, ASAIOJ 2009)
- 2011 TLV efficacy in an ovine model of meconium aspiration syndrome (Avoine et al Crit Care Med, 2011)
- 2015 Hypothermic TLV is protective after cardiac arrest (Kohlhauer et al, crit Care Med 2015)

# Total- (TLV) vs Partial- (PLV) liquid ventilation



Liquid-Gas interface  
(surfactant)

Liquid-Liquid interface  
(↓ tension)

Some PFC coat alveoli, others form droplets.  
Inhomogeneity across lungs

# Why EIT?

## Challenges of TLV

- Monitoring of quantity/location of PFOB
- Induction phase, during which a mixture of air and fluid is in the lung.

**Hypothesis:** EIT can help clarify the time courses of distributions of air and PFOB

**Previous work:** Wolf *et al* 2010<sup>1</sup> studied EIT and liquid ventilation, but did not address the induction phase.

# Experimental Protocol

- Supine lamb (term), tracheotomy, conventional ventilation
- Instrumentation: EIT electrodes (SigmaTôme II), Arterial & Venous lines
- Conventional (air) ventilation: Pressure controlled
- PFOB filling
- TLV ventilation: volume controlled mode (60 minutes)
- PFOB emptying
- Conventional (air) ventilation: Pressure controlled
- Euthenasia of animal

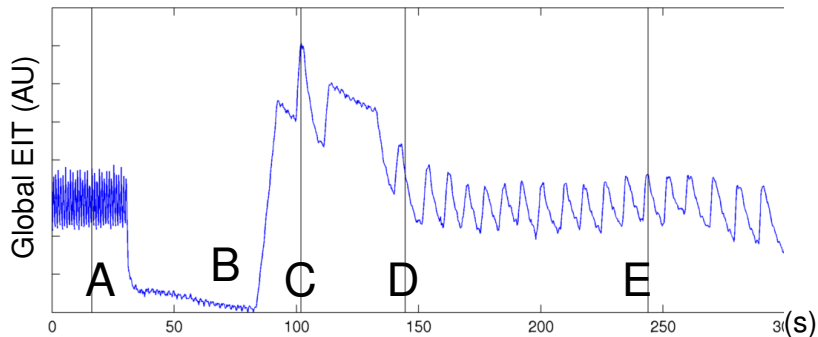


Inolivent-6  
Liquid Ventilator

Guaranteed TV  
Pressure Limited  
2 volumetric pumps  
4 valves

# Results: Induction phase

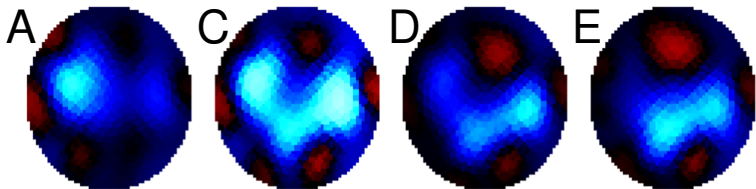
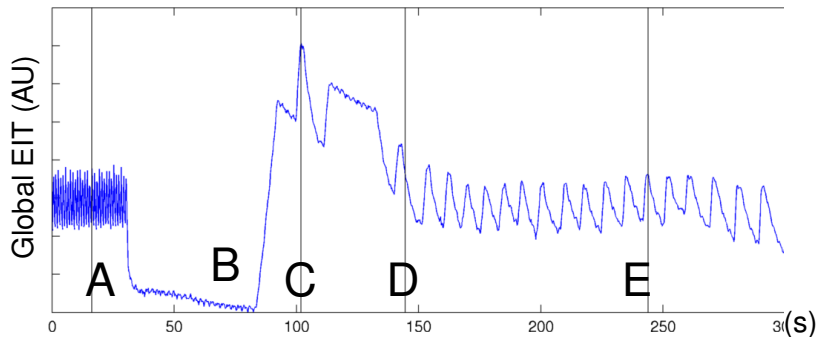
A:Conventional, B:Disconnect, C:Filling, D,E:TLV





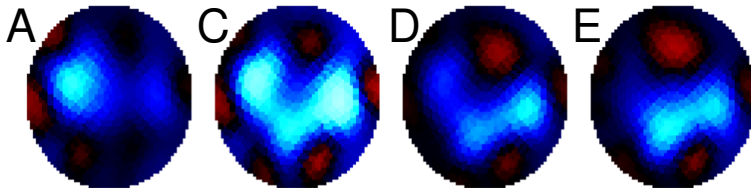
# Results: Induction phase

A:Conventional, B:Disconnect, C:Filling, D,E:TLV



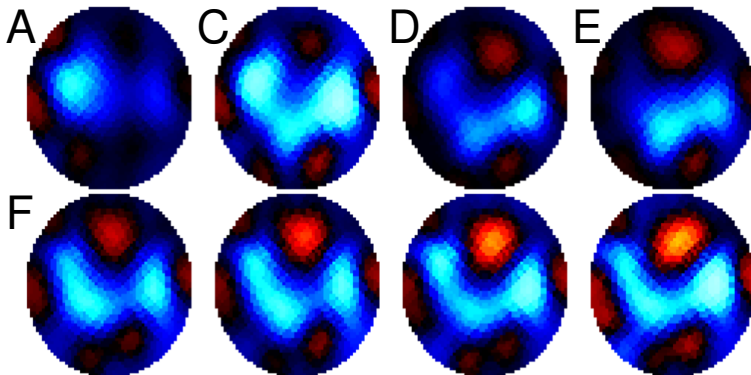
# Results: Induction & Stabilization Phase

A:Air C:+20s D:+80s E:+180s E:+180s F:+7min G:+30min



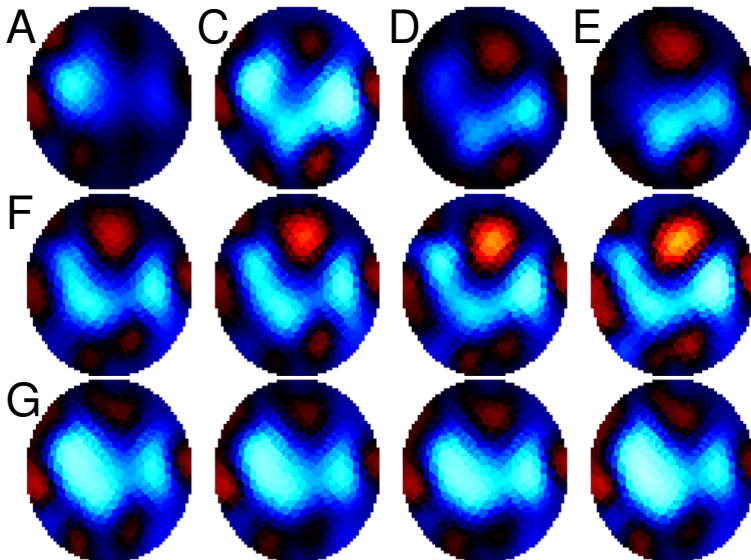
# Results: Induction & Stabilization Phase

A:Air C:+20s D:+80s E:+180s E:+180s F:+7min G:+30min



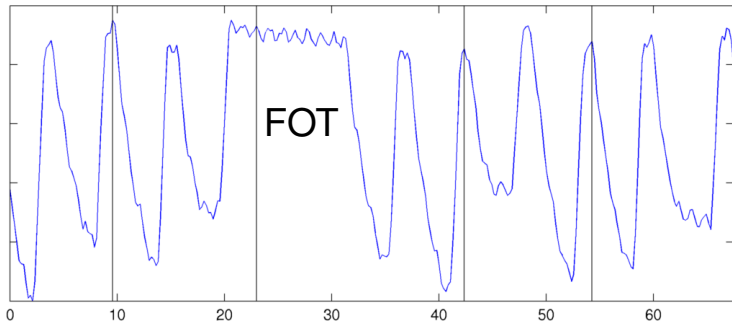
# Results: Induction & Stabilization Phase

A:Air C:+20s D:+80s E:+180s E:+180s F:+180s F:+180s G:+7min G:+30min



# Distinguish Air / PFOB with forced oscillation?

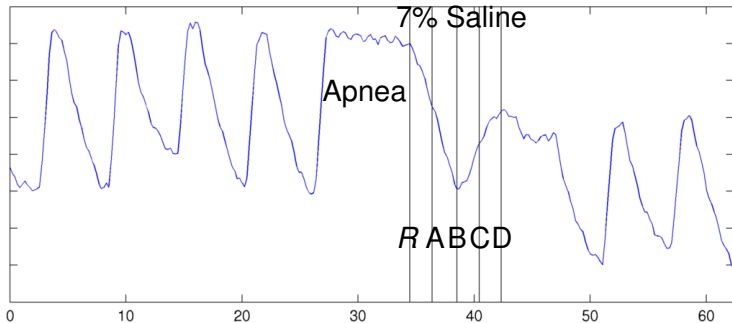
Problem: PFOB and Air are both non-conductive; how to distinguish?



Protocol: 2 Hz Forced oscillation of Liquid should couple to liquid more strongly than air

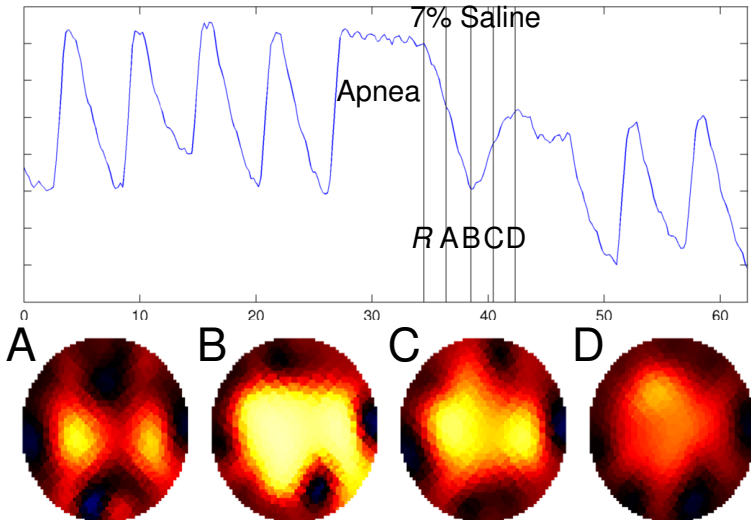
# Perfusion during Liquid Ventilation

Problem: What happens to lung perfusion during TLV?



# Perfusion during Liquid Ventilation

Problem: What happens to lung perfusion during TLV?



# Discussion

- EIT can help understand the physiology during liquid ventilation.
  - Initially: PFC in dependent, gas more non-dependent lung.
  - over time, redistribution of ventilation → more uniform.
- Next step: currently performing a larger ( $N = 10$ ) study, which will include EIT and fluoroscopy
- How to separate air and PFC in images?



# EIT monitoring of the liquid-ventilated lung

Thanks!

## References

1. GK Wolf, B Grychtol, TK Boyd, D Zurakowski, JH Arnold, “Regional overdistension identified with electrical impedance tomography in the perflubron-treated lung”, 31:S85–S95, 2010
2. MR Wolfson, TH Shaffer, “Pulmonary applications of perfluorochemical liquids: Ventilation and beyond”, Paediatric Resp Reviews 6:117–127, 2015
3. Avoine O, Boss D, Beaudry B, Beaulieu A, Albadine R, Praud JP, Robert R, Micheau P, Walti H. “Total liquid ventilation efficacy in an ovine model of severe meconium aspiration syndrome.” Crit Care Med. 2011 May;39(5):1097–103.
4. Sage M, Nadeau M, Kohlhauer M, Praud JP, Tissier R, Robert R, Walti H, Micheau P. “Effect of ultra-fast mild hypothermia using total liquid ventilation on hemodynamics and respiratory mechanics”. Cryobiology. 2016 May 27 PubMed PMID: 27242031.
5. Robert R, Micheau P, Cyr S, Lesur O, Praud JP, Walti H. “A prototype of volume-controlled tidal liquid ventilator using independent piston pumps.” ASAIO J. 2006 Nov-Dec;52:638–45.

# EIT monitoring of the liquid-ventilated lung

Andy Adler, Étienne Fortin-Pellerin, Mathieu Nadeau, Jonathan Vandamme, Julien Mousseau, Philippe Micheau, Michaël Sage, Jean-Paul Praud.

**Introduction:** Total liquid ventilation uses liquid perflubron instead of air for gas exchange. It has several possible applications, especially for the immature lungs of extremely premature neonates, and in the damaged lungs of ARDS patients. Since perflubron is dense ( $\rho \approx 2$ ) it helps keep open dependent lung regions which can be collapsed (atelectatic) or undergo cyclical opening with traditional positive-pressure ventilation. One clear challenge with liquid ventilation is the induction phase, during which a mixture of air and fluid is in the lung. We are hopeful that EIT can help clarify the time courses of distributions during this phase, and thus help improve strategies for induction. One previous report studied EIT and liquid ventilation [1], but did not address the induction phase.

**Objective:** To investigate whether EIT can help clarify the distribution of ventilation during the liquid-ventilation induction phase.

**Methods:** One healthy lamb (male, age 3 days, 4.2 kgs) was anesthetized and ventilated in a supine position using pressure control ventilation (PIP 14 cmH<sub>2</sub>O, PEEP 4 cm H<sub>2</sub>O). Sixteen EIT electrodes were attached in a transverse plane and images acquired at 4.7 frames/s using the Sigatome II EIT device. During the experimental phase of interest, the ventilator was disconnected and perflubron was introduced and liquid ventilation commenced.

**Results:** Images were reconstructed using a GN algorithm with electrode movement compensation. The figure shows the global EIT image (arbitrary units, non-conductive changes are positive) vs. time (seconds). At four instants (vertical lines) the EIT image is shown. Phases of A) air ventilation, D) disconnection, L) liquid ventilation are seen. Images show a movement of the ventilated region in the dependent direction. From L2 and L3 show a stable ventilated region in the dependent lungs. L1 appears to show both air and liquid in the lungs.

**Discussion:** EIT images appear to show useful information about the physiological changes during the induction of liquid ventilation. As understood, the perflubron ventilation occurs primarily in the dependent lobes of the lung, while gas ventilation occurs more ventrally. We see an initial phase where both air and fluid are seen in the lungs. In further monitoring over the next 30 minutes (not shown) there is a redistribution of ventilation to achieve a more uniform pattern. These results suggest EIT can help understand the physiological changes during liquid ventilation.

## References:

1. GK Wolf, B Grychtol, TK Boyd, D Zurakowski, JH Arnold, "Regional overdistension identified with electrical impedance tomography in the perflubron-treated lung", 31:S85–S95, 2010