

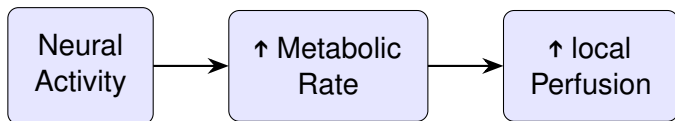
# *Cerebral perfusion imaging using EIT*

Andy Adler<sup>1</sup>, Mayo Faulkner<sup>2</sup>, Kirill Aristovich<sup>2</sup>,  
Sana Hannan<sup>2</sup>, James Avery<sup>2</sup> & David S. Holder<sup>2</sup>

<sup>1</sup>Systems and Computer Eng., Carleton University, Ottawa, Ontario, Canada  
<sup>2</sup>Medical Physics and Biomedical Engineering, University College London, UK

EIT 2017  
June 21–24, Dartmouth College  
Hanover, New Hampshire, USA

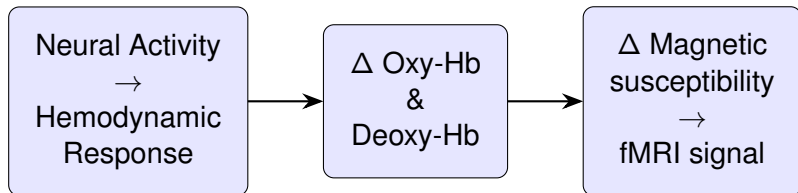
# Hemodynamic Reponse



- ↑ blood flow to deliver  $O_2$  and glucose to stressed tissues
- mechanism: dilation of smooth muscle when NO released from endothelial cells

# fMRI BOLD response

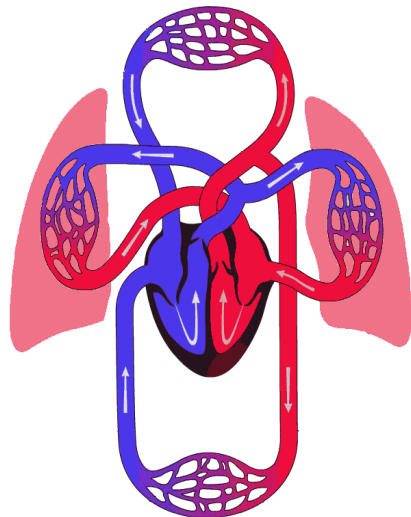
Cerebral imaging using fMRI plays an important role in functional studies of the brain.



BOLD  $\triangleq$  Blood-oxygen-level dependent contrast imaging

## Question: perfusion with EIT?

Thoracic/lung perfusion imaged using injection of a bolus of hypertonic saline<sup>1</sup>.



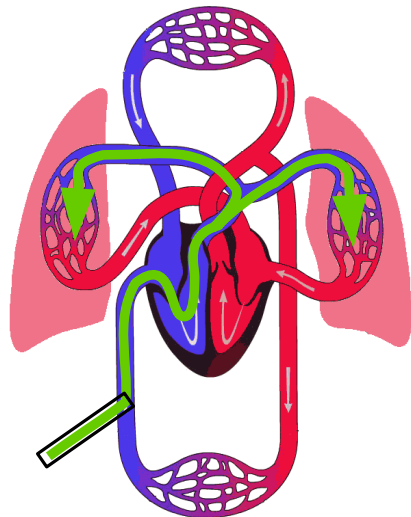
<sup>1</sup> Frerichs, et al, *IEEE T Med Imag* 21:646, 2002.

<sup>2</sup> Image modified from: Urgo Medical, [www.urgomedical.com](http://www.urgomedical.com)

## Question: perfusion with EIT?

Thoracic/lung perfusion imaged using injection of a bolus of hypertonic saline<sup>1</sup>.

Injection into femoral vein



<sup>1</sup> I Frerichs, et al, *IEEE T Med Imag* 21:646, 2002.

<sup>2</sup> Image modified from: Urgo Medical, [www.urgomedical.com](http://www.urgomedical.com)

# Question: detect **brain** perfusion with EIT?

## Pilot Experiments in a rat

- Scousetom EIT system<sup>2</sup>
- 57 electrodes on cortical surface
- 5 frames/sec, 50  $\mu$ A at 2 kHz

---

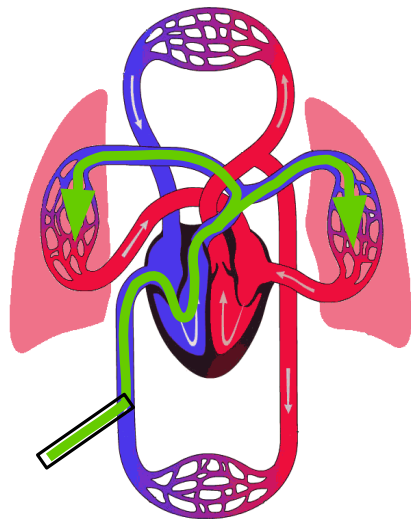
<sup>2</sup>J Avery, T Dorrick, M Faulkner, N Goren, D Holder. *Sensors*, 17:280, 2017

# Method #1: bolus via vein

Contrast:

500  $\mu\text{L}$  of 10% NaCl (w/v)

Injection via femoral vein

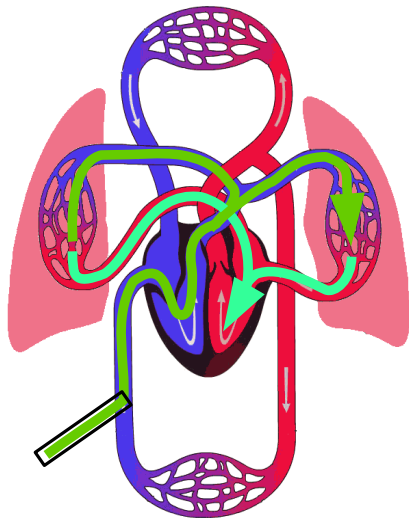


# Method #1: bolus via vein

Contrast:

500  $\mu\text{L}$  of 10% NaCl (w/v)

Injection via femoral vein





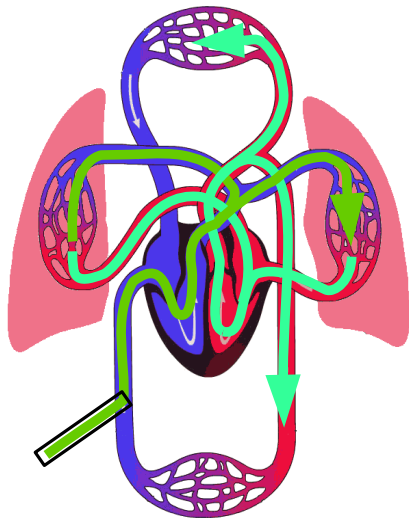
# Method #1: bolus via vein

Contrast:

500  $\mu\text{L}$  of 10% NaCl (w/v)

Injection via femoral vein

*No signal seen*

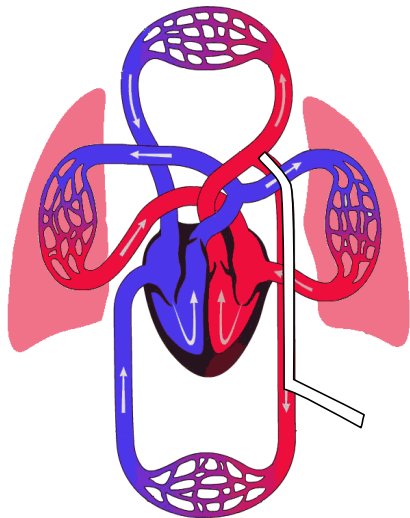


## Method #2: bolus at aortic arch

Contrast:

500  $\mu\text{L}$  of 10% NaCl (w/v)

Catheter into femoral artery to  
aortic arch (determined by  
pressure waveform)



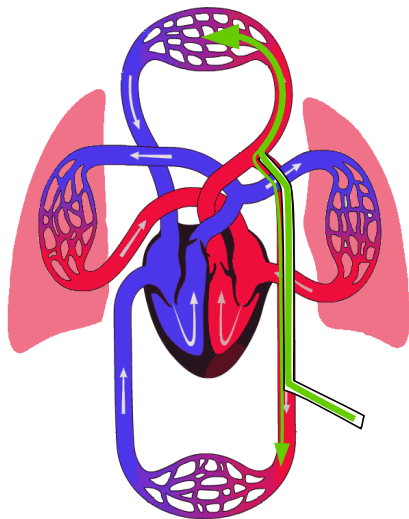
## Method #2: bolus at aortic arch

Contrast:

500  $\mu$ L of 10% NaCl (w/v)

Catheter into femoral artery to  
aortic arch (determined by  
pressure waveform)

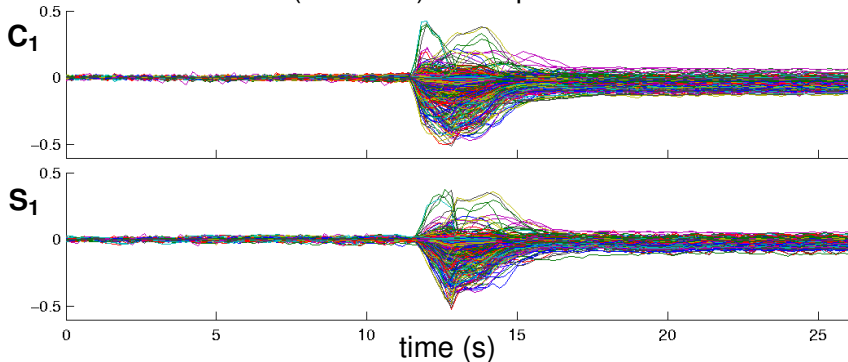
*"It'll only take 5 minutes"*



# Raw Measurements


Protocol:  $C_1$ ,  $S_1$ ,  $C_2$ ,  $S_2$ .

- $C \triangleq$  Control (no stimulation).
- $S \triangleq$  Simulation (electrical) of forepaw



Raw EIT recordings  $C_1$ ,  $S_1$  w.r.t. to baseline ( $t = 0$ ) values.

# Raw images

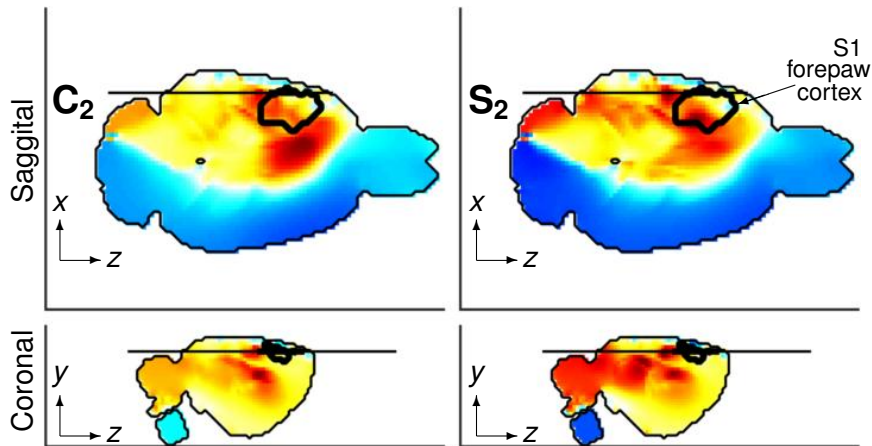


Time sequence of EIT images of a horizontal slice (Red  $\uparrow\sigma$ , Blue  $\downarrow\sigma$ ), from left to right; images spaced by 600 ms.

- C<sub>1</sub>, C<sub>2</sub>: control (no stimulation).
- S<sub>1</sub>, S<sub>2</sub>: with forepaw stimulation.

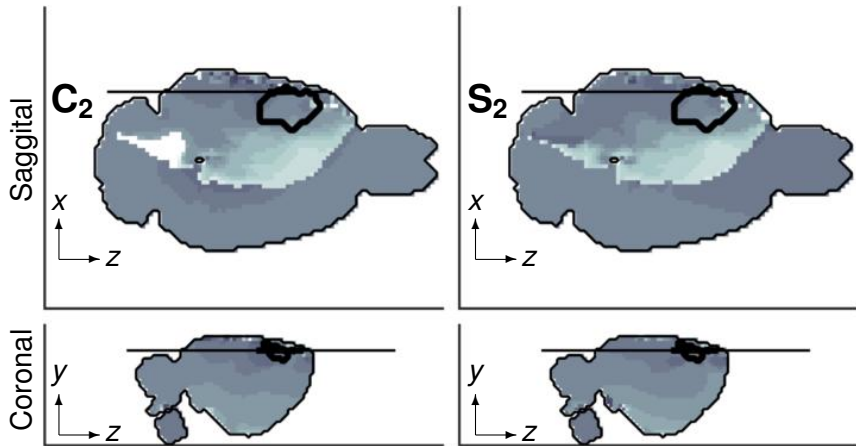


# Maximum images



Images show maximum EIT voxel signed value.

## Image: Activation time



Images show time of maximum EIT activation (light=earlier)

# Discussion

- Can EIT see brain perfusion?



# Discussion

- Can EIT see brain perfusion?

Yes

# Discussion

- Can EIT see brain perfusion?
- Can EIT see functional differences in perfusion?

Yes

# Discussion

- Can EIT see brain perfusion? Yes
- Can EIT see functional differences in perfusion? Maybe

# Discussion

- Can EIT see brain perfusion?
- Can EIT see functional differences in perfusion?
- Will EIT replace your \$5M MRI machine?

Yes

Maybe

# Discussion

- Can EIT see brain perfusion?
- Can EIT see functional differences in perfusion?
- Will EIT replace your \$5M MRI machine?

# Discussion

- Can EIT see brain perfusion?
- Can EIT see functional differences in perfusion?
- Will EIT replace your \$5M MRI machine?

What does EIT offer for this application?

- Cheap
- Small
- High temporal resolution
- Invasive
- Low spatial resolution